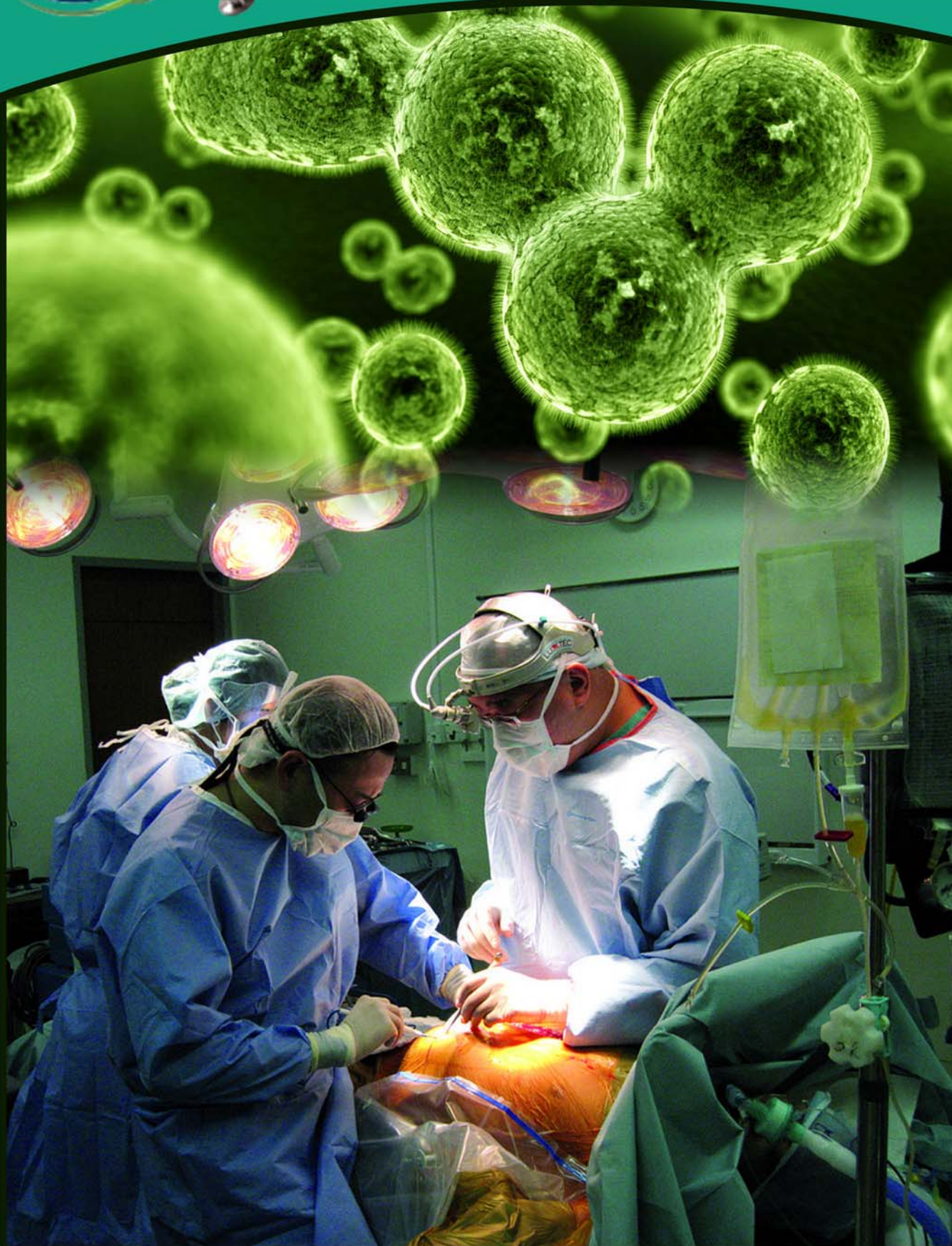



International Journal of Medical Sciences and Pharma Research

www.ijmspr.com





Case Report

SIMULTANEOUS BILATERAL SHOULDER DISLOCATION: A CASE REPORT

Mohammed Jalal Mohiuddin¹, Hashmi Syed Salman Hamid^{2*} and Shaik Ajaz¹

*Corresponding Author: **Hashmi Syed Salman Hamid** ✉ syedsalmanhhashmi@yahoo.com

Introduction: Bilateral shoulder dislocations are relatively uncommon. Bilateral shoulder dislocation was first described in 1902, because of muscular contractions in camphor overdose. Among the bilateral shoulder dislocation posterior are most common usually following convulsions or electric shocks. Simultaneous bilateral anterior dislocations of shoulder following trauma is a rare occurrence. **Case Report:** A 28 year old male presented to emergency department with history of fall on outstretched hand. He complained of pain and difficulty in moving both the shoulders. On clinical examination, patient's both upper limbs were abducted and externally rotated. Bilaterally shoulder contour was lost with flattening. Other classical signs of shoulder dislocation like Bryants test, Callway sign, Hamilton's ruler test were positive. Diagnosis was confirmed on X rays. Both shoulders were reduced in emergency operation theater under general anaesthesia by Kocher's method and were immobilized in sling. **Conclusion:** Simultaneous bilateral dislocation of the shoulder are uncommon during clinical practice but have to be diagnosed and adequately treated. Though posterior shoulder dislocations are common secondary to convulsions and electric shocks anterior shoulder dislocations should be kept in mind. The bilateral dislocations also presents with practical problem of immobilization of both limbs and day to day care of patients. Hence the dislocations require special attention and proper care .

Keywords: Simultaneous, Bilateral, Shoulder dislocation, Traumatic

INTRODUCTION

Bilateral shoulder dislocation was first described in 1902 (Mynter H) because of muscular contractions in camphor overdose. Anterior dislocation of shoulder is the most common dislocation found in orthopaedics practice but bilateral shoulder dislocations are relatively uncommon (Bouras *et al.*, 2009). Common

mechanism of injury is fall on outstretched hand. Among the bilateral shoulder dislocation posterior are most common usually following convulsions or electric shocks. Shoulder dislocations are common due unstable configuration of the shoulder joint that is shallow glenoid cavity and globular head. The wide range of movement predispose the joint for dislocations. Bilateral

¹ Department of Orthopaedics, Deccan College of Medical Sciences, Hyderabad, Telangana, India.

² House Surgeon, Deccan College of Medical Sciences, Hyderabad, Telangana, India.

shoulder dislocations are also associated with fracture of the humerus. The following case is of bilateral anterior shoulder dislocation following trauma. There have been few such cases reported in the literature and the following case would add to the existing knowledge about this relatively rare entity.

CASE REPORT

A 28 year old male patient came to the emergency department with complain of pain and difficulty moving both the shoulder joints following fall on an outstretched hand (Figure 1). The patient did not give any history of present or past convulsions and any neuromuscular disorders.

Figure 1: Picture Showing the Patient

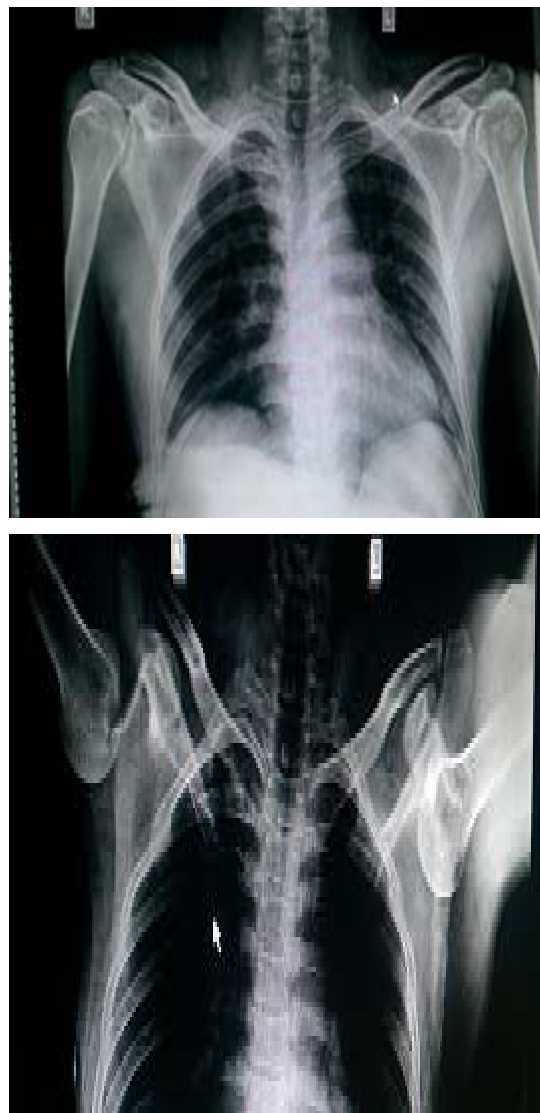


On clinical examination both the shoulder joints were abducted and externally rotated. Bilateral shoulder joints contour was lost with flattening. There was no neurovascular deficit.

Other classical signs of dislocation like the Callway sign and Bryants test were positive. Radiograph of both the joints was obtained and clinical diagnosis was confirmed (Figures 2 and 3).

Both the shoulder joints were reduced in the emergency operation theater under general anesthesia by Kocher's method and immobilized by sling. Reduction was confirmed post operatively by X-ray. Intermittent assisted exercise was started from second week over isolated

Figures 2 and 3: X-ray Films Showing Bilateral Anterior Dislocation of Both Shoulder Joints



dislocation side and after 4 weeks on the greater tuberosity fracture side. After the immobilization period patient was advised supervised physiotherapy.

DISCUSSION

Bilateral shoulder dislocation are commonly seen post convulsion and electric shock (Brown, 1984).

These are usually posterior dislocation but anterior dislocation with fracture of greater

tuberosity are also seen (Suryavanshib *et al.*, 2012). Dunlop *et al.* (2002) in his case report and literature review found that most of the cases are associated with fractures. He also found that of the 30 cases, 5 were diagnosed late (Sunku *et al.*, 2012). Singh and Kumar (2005) have reported a case of sequential bilateral dislocation in which the left shoulder dislocated first due to trauma followed by the a traumatic dislocation of right shoulder. Bilateral anterior shoulder dislocations themselves are unusual and post reduction they cause a practical problem in day to day activities due to immobilization position of both upper limb. Yeshwanth *et al.* (2013) focused on mechanism of injury and commented on the important role of forced extension, abduction and external rotation. In our case the patient fell on the outstretched hand which may have caused forced extension and external rotation.

Ballestrouses *et al.* (2013) found that simultaneous bilateral dislocation of the shoulder are common in young males and middle aged women most common cause being trauma (50%) followed by strong muscular contraction secondary to convulsions (37%). They stated that bilateral anterior dislocation are not rare and radiological diagnosis must be stressed upon. As stressed in these papers the treatment plan is same as that of unilateral shoulder dislocation but as both upper limbs are immobilized the practical problem caused to the patient is more. Ballestrouses *et al.* proposed early and aggressive rehabilitation program for better outcome of the cases. The prognosis doesn't differ from unilateral cases and follow up result seem to be dependent on severity of initial injury rather than the bilateralism of the injury.

CONCLUSION

Simultaneous bilateral dislocation of the shoulder are uncommon during clinical practice but have to be diagnosed and adequately treated. Though posterior shoulder dislocations are common secondary to convulsions and electric shocks anterior shoulder dislocations should be kept in mind .Literature suggest that about 10% cases of bilateral anterior shoulder dislocation cases are diagnosed late (5). The bilateral dislocation also presents with practical problem of immobilization of both limbs and day to day care of patients. Hence the dislocations require special attention and proper care .

ACKNOWLEDGMENT

We would like to thank the Department of Orthopaedics and the patient for their co-operation.

REFERENCES

1. Ballesteros R, Benavente P, Bonsfills N, Chacón M and García-Lázaro F J (2013), "Bilateral anterior dislocation of the shoulder: review of seventy cases and proposal of a new etiological-mechanical classification", *J. Emerg Med.*, Jan; Vol. 44, No. 1, pp. 269-79.
2. Bouras Y, Elandaloussi Y, Nadil M A, Essarouli A, Bennouna D, Fadili M and Quara M (2009), "Bilateral anterior dislocation of shoulders(case report) (*Luxation Antereure bilaterale des epaules chez le bodybuilder (a propos daeun cas)*)", *Journal de Traumatologie du Sport*, Vol. 26, No. 4, pp. 247-249.
3. Brown R J (1984), "Bilateral dislocation of the shoulders", *Injury*, Vol. 15, pp. 267–732.
4. Dunlop C C (2002), "Bilateral anterior

- shoulder dislocation—a case report and review of the literature”, *Acta Orthop Belg.*, Vol. 68, No. 2, pp. 168-70.
5. Mynter H (1902), “Subacromial dislocation from muscular spasm”, *Ann. Surg.*, Vol. 36, pp. 117-119.
 6. Suryavanshib A, Mittal A, Dongre S and Kashyap N (2012), “Bilateral Anterior Shoulder Dislocation with Symmetrical Greater Tuberosity Fracture following Seizure”, *Journal of Orthopaedic Case Reports*, Vol. 2, No. 1, pp. 28-31.
 7. Sunku N, Kalaiah K, Marulasidappa G and Gopinath P (2012), “Greater Bilateral Anterior Fracture-Dislocation of Shoulder Joint”, *Journal of Orthopaedic Case Reports*, Vol. 2, No. 4, pp. 7-9.
 8. Singh S and Kumar S (2005), “Bilateral anterior shoulder dislocation: a case report”, *European Journal of Emergency Medicine*, Feb; Vol. 12, No. 1, pp. 33-5.
 9. Yashwantha K C, Nalini K B, Maini Lalit and Nagaraj P (2013), “Bilateral traumatic anterior dislocation of shoulder, a rare entity”, *Journal of Orthopaedic Case Reports*, Jan-March, Vol. 3, No. 1, pp. 23-25.



International Journal of Medical Sciences and Pharma Research
1120 S Walton Blvd, Suite 138, Bentonville, Arkansas - 72712-0077, USA.
www.ijmspr.com

